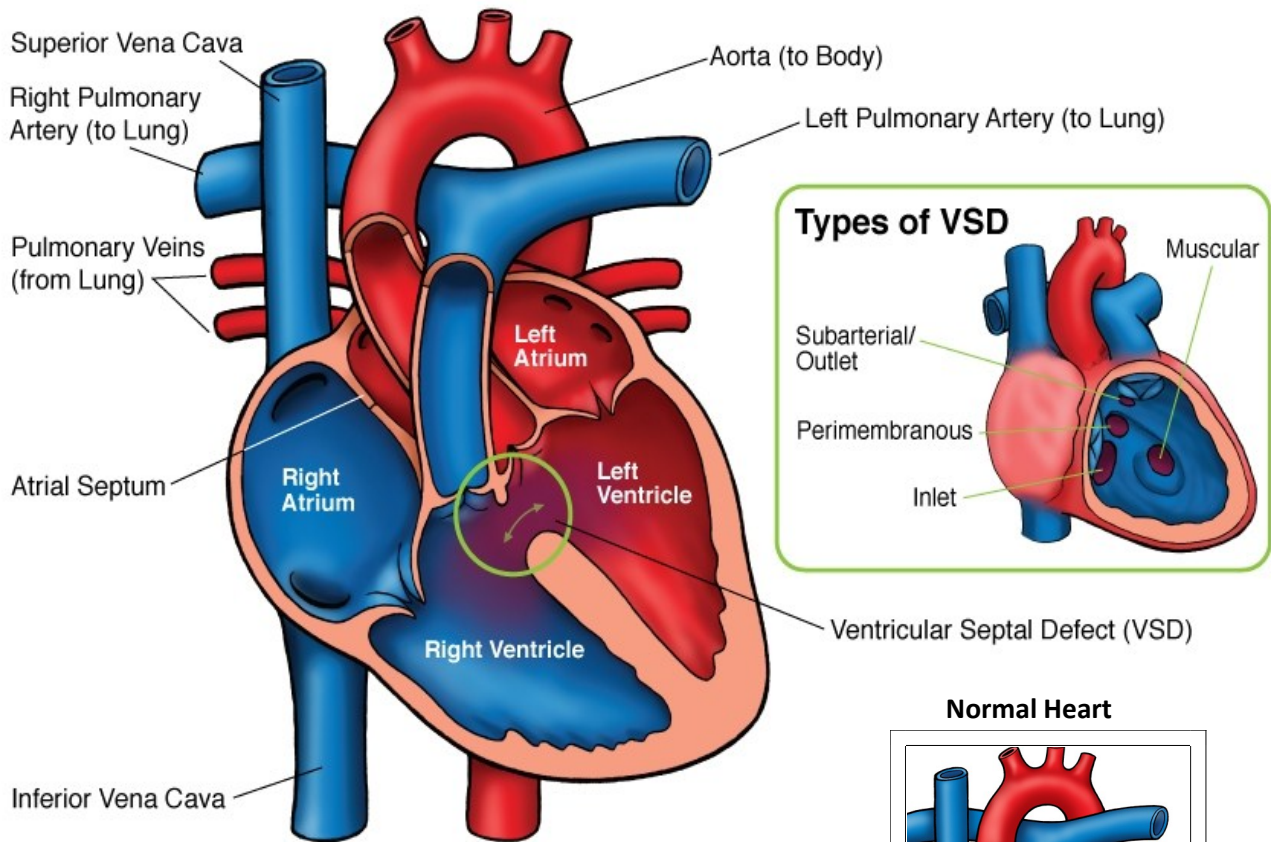




Ventricular Septal Defect (VSD)



NOTES:

Ventricular Septal Defect (VSD)

A ventricular septal defect (VSD) is a hole between the lower two chambers of the heart (ventricles). VSDs are the most common type of congenital heart disease (20% of all cardiac defects). VSDs may also occur in conjunction with other heart defects. There are several types of VSDs, classified by their location on the ventricular septum.

Types:

- Perimembranous: Located in beneath the aortic valve. These are the most common type of VSD (70%).
- Outlet (infundibular or conal): Located within the outlet (conal) septum. Part of the rim of this VSD comprises the pulmonary and aortic annulus. Outlet VSDs account for 5-7% of VSDs.
- Inlet (AV canal): Located posterior and inferior to the perimembranous defect, below the tricuspid valve septal leaflet. Inlet VSDs account for 5-8% of VSDs.
- Muscular (Trabecular): Midmuscular VSDs are located posterior to the septal band. Apical muscular defects are located near the cardiac apex. Some patients have multiple muscular VSDs present. This type accounts for 5-20% of all VSDs.

Physical Exam/Symptoms:

- Children with small VSDs are asymptomatic. A regurgitant systolic murmur is heard best at the left lower sternal border. A systolic thrill may be palpable. The intensity of the murmur does not reflect the size or degree of symptoms.
- Large VSDs may be associated with delayed growth and development, symptoms of pulmonary infections, exercise intolerance and poor feeding. Symptoms of congestive heart failure usually develop within 6-8 weeks of age in children with large VSDs. Pulmonary hypertension may also occur.
- Older children with unrecognized large VSDs may have cyanosis (blue color) and clubbing as a result of pulmonary obstructive disease (Eisenmenger's syndrome).

Diagnostics:

- Chest X-ray: Varying degrees of cardiomegaly (enlarged heart) is present with increased pulmonary vascular markings relative to the amount of left to right shunting.
- EKG: Evidence of left atrial and/or left ventricular enlargement.
- Echocardiogram: Diagnostic

Medical Management/Treatment:

- 30-40% of *muscular and membranous* VSDs close within the first 6 months or become smaller with age. *Inlet and outlet* VSDs do not close spontaneously or get smaller with age.
- Medications, such as diuretics and ACE inhibitors, and/or high-calorie formula/fortified breast milk may be used to allow time for spontaneous closure or to delay surgical treatment.
- VSDs can be closed surgically (see [VSD repair](#)). Some muscular VSDs may be closed with a device in the cath lab.
- Cardiology follow up is recommended through childhood.
- No activity restrictions or long-term medications are needed for children who have spontaneous closure or surgical repair of their VSDs in the absence of other heart disease.

Long-Term Outcomes:

- Normal life expectancy
- Bacterial endocarditis prophylaxis is discontinued 6 months after closure/repair if no residual shunt/cardiac lesion.